

## THE CERVICAL MUSCULATURE IN HELODERMATID LIZARDS

ANTHONY HERREL AND FRITS DE VREE

Department of Biology, University of Antwerp (UIA),  
Universiteitsplein 1, B-2610 Antwerp, Belgium  
e-mail : aherrel@uia.ua.ac.be

**Abstract.** The evolution of an independently moveable craniocervical system is a key feature in the evolution of amniote organisms. The cervical system not only plays a crucial role during the orientation of the head towards external stimuli (*e.g.* visual, auditory stimuli), but is also of major importance during the inertial components of feeding in amniotes. Although the cervical system and its musculature are generally well studied in mammals, archosaurs (birds and crocodiles) and turtles, very little is known about the cervical system in some of the most primitive amniotes (lepidosaurians). In a first step towards elucidating the evolution of the cervical system, we examined the neck musculature in lizards of the family Helodermatidae. In general, the bauplan of the cervical muscular system appears stable within closely related phylogenetic groups. Nevertheless, preliminary data suggest that the evolutionary shift from a lingual-based to a predominantly inertial feeding system within lizards coincides with an increase in the complexity of mainly the epaxial components of the cervical musculature. A "new" comprehensive nomenclature of lizard neck muscles (based on the work of NISHI, 1916) is proposed, and should enable future workers to interpret the neck musculature in an evolutionary context.

*Key words* : cervical musculature, lizard, functional morphology, Helodermatidae, inertial feeding.

### INTRODUCTION

The evolution of an independently moveable cranial and cervical system is a key novelty in the evolution of amniote organisms (GANS, 1992). About 300 million years ago (JOUFFROY, 1992), the first two vertebrae (atlas and axis) became modified, which permitted bending and rotation between the cranial and cervical system, and thus movements of the head relative to the rest of the body. This independent head movement was crucial for the first land vertebrates as it increased their sensory abilities, and opened new avenues to orient towards, or away from, stimuli (visual, auditory, olfactory), discover food sources, catch prey, etc. The cervical system not only plays a crucial role during orientation of the head, but it is also of major importance during the inertial components of feeding (see GANS, 1969) in terrestrial amniotes such as lizards (SMITH, 1982), crocodiles (CLEUREN & DE VREE, 1992; CLEUREN, 1996), birds (ZWEERS, 1982), and mammals (GORNIAK & GANS, 1980). Although the cervical system and its musculature are generally well studied in mammals (*e.g.* RINKER, 1954; RICHMOND & ARMSTRONG, 1988; JOUFFROY, 1992), archosaurs [birds (*e.g.* BOAS, 1929; VANDEN BERGHE & ZWEERS, 1993; ZWEERS *et al.*, 1994) and

crocodiles (e.g. SEIDEL, 1978; FREY, 1988; CLEUREN, 1996)] and turtles (e.g. GEORGE & SHAH, 1954, 1955; SHAH, 1963; SCANLON, 1982), little is known about the cervical system in some of the most primitive amniotes such as lizards (NISHI, 1916; VALLOIS, 1922; OELRICH, 1956). The presence, position and orientation of neck muscles are, however, used as systematic characters in the classification of lizard groups (RIEPEL, 1980).

The aim of the present study is to compare the neck musculature of a derived group of lizards (helodermatids) with previously published data on other lizards, and to re-evaluate the present nomenclature of the cervical musculature. With increased knowledge about the complexity of the lizard cervical system, an attempt can be made to characterise evolutionary patterns of the cervical musculature within lizards, and to elucidate functional correlates of these patterns during feeding.

## MATERIAL AND METHODS

One specimen of *Heloderma horridum*; Wiegmann, 1829 (Smithsonian Institution) and one *Heloderma suspectum* Cope, 1869 (Carnegie Museum of Natural History) were used for the detailed morphological analysis.

All specimens examined were dissected and stained (BOCK & SHEAR, 1972) to characterise the cervical musculature. Drawings were made of all stages of the dissection using a Wild M5 dissecting microscope, equipped with a camera lucida.

## RESULTS

The structure of the cervical vertebrae in reptiles has been discussed previously, so it is not discussed in detail here. For an excellent overview of the complexity and diversity of the cervical vertebrae in lizards we refer to HOFSTETTER & GASC (1969). Only some striking differences between the representatives of the groups examined here are mentioned. Whereas most lizard groups possess eight cervical vertebrae, varanids have one extra. Notable is the remarkable reduction of the hypapophyses in Helodermatidae (Fig. 1). Cervical ribs occur in all specimens studied. Whereas the first cervical ribs attach to the fourth cervical in the Iguanidae, Scincidae, and Helodermatidae examined here, in the Agaminae and Leiolepidinae the first pair of cervical ribs attaches to the fifth cervical vertebra (Fig. 2). In varanids the first cervical ribs usually attach to the sixth cervical vertebrae (see HOFSTETTER & GASC, 1969). The nomenclature of the various parts of the cervical vertebra is indicated on Fig. 1.

The cervical musculature in *Heloderma* is described briefly, and compared with that in representatives of other lizard families. The cervical system of *Heloderma* was chosen as it shows the full complexity observed within lizards. In general, the muscle nomenclature of NISHI (1916) and OELRICH (1956) is used, unless mentioned otherwise. Some muscles associated with the pectoral girdle and situated in the cervical region are also described for clarity. For these muscles the terminology of SANDERS (1870, 1872, 1874) is used.

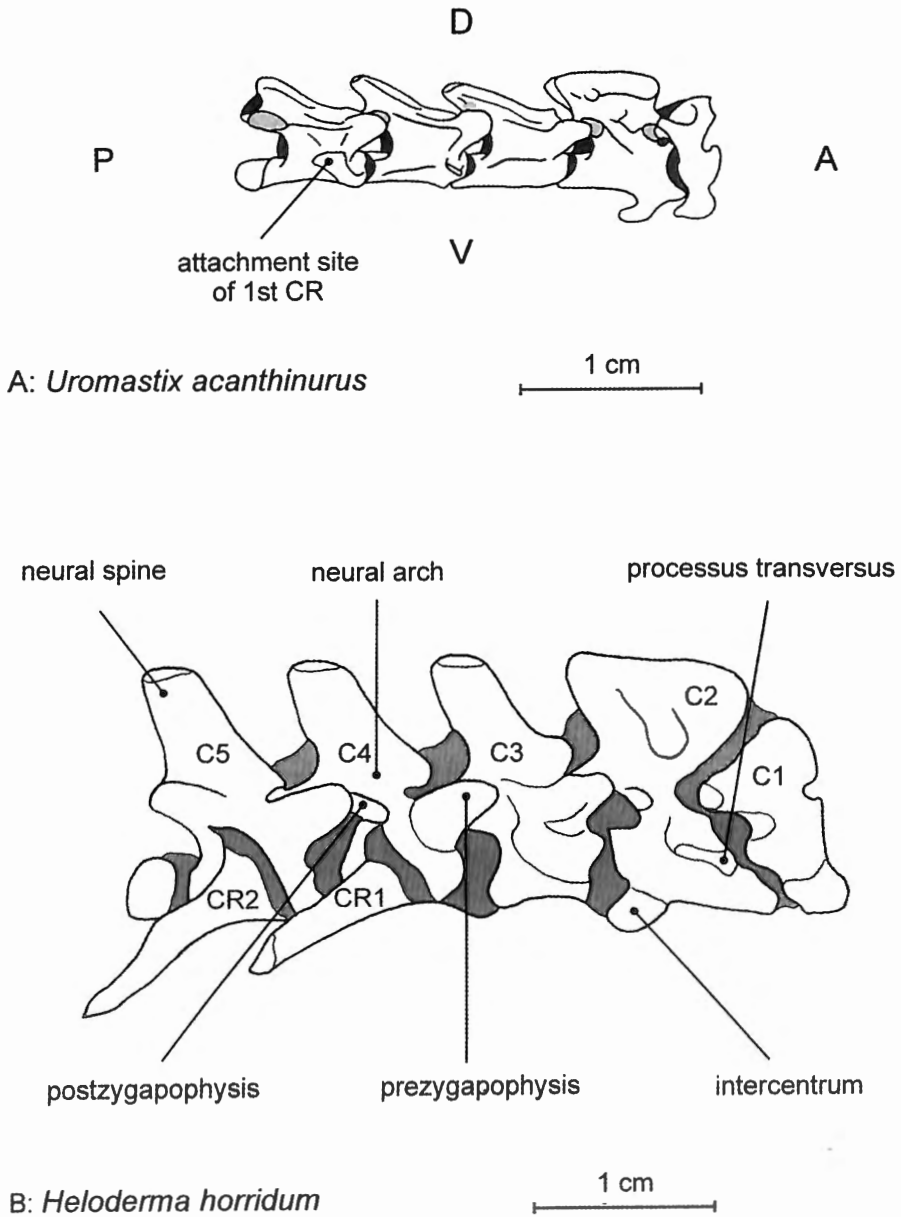


Fig. 1. — *A*: first five cervical vertebrae of *Uromastix acanthinurus*. Note that the first cervical rib has been removed. — *B*: ligamentous preparation of the first five cervical vertebrae in *Heloderma horridum*.

The shaded area represents connective tissue. Both drawings are at the same scale (6.5 x magn.) and oriented with the cranial side to the right. A, anterior; C, cervical vertebra; CR, cervical rib; D, dorsal; P, posterior; V, ventral.

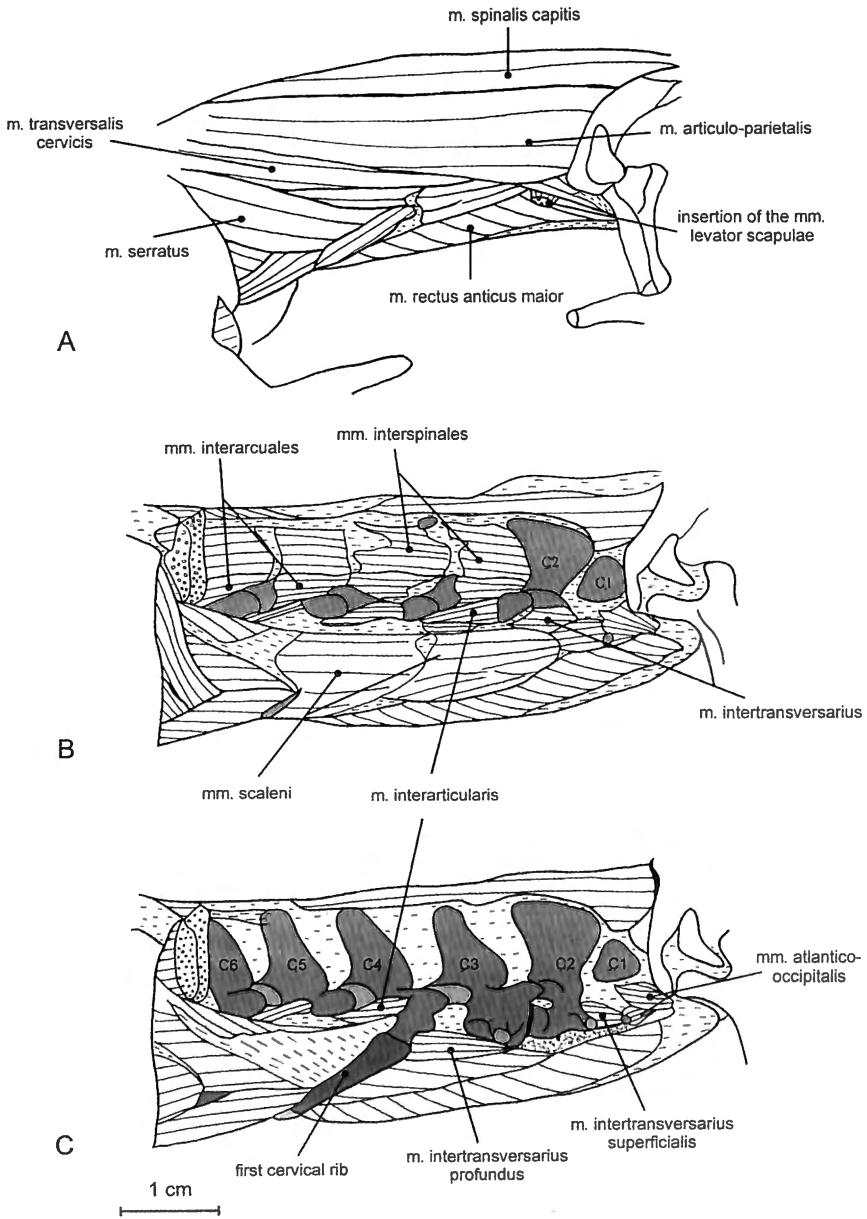


Fig. 2. — Neck musculature. — *A*: superficial lateral view on the neck musculature in *Heloderma suspectum*. The MLSS, MLSP, MEM, MT, the m. depressor mandibulae, the m. cervicommandibularis and the m. constrictor colli have been removed. — *B*: *Heloderma horridum*, deeper level of dissection after removal of the MSCe, the MSSCe, the MOCa, the MICoCa, the MICoCe, the right MSCa and the MLCeCa complex. — *C*: as in *B*, but after removal of the MIS, the MIARC, the MS and some MIART and MIT (for an explanation of abbreviations, see results).

### The transverso-spinalis complex

\* The *m. spinalis capitis* (MSCa), the dorsal-most neck muscle, lies adjacent to the ligamentum nuchae, and mesially with respect to all other neck muscles. The muscle originates at the dorsolateral side of the neural spines of cervical vertebrae 2 to 5 (C2-C5). The fibres run anteriorly and insert at the mediocaudal aspect of the parietal bone. A small slip of this muscle, arising at the C1-C2 junction, runs a little ventrad and inserts at the occipital crest of the supraoccipital bone (see OELRICH, 1956).

\* The *mm. spinalis* and *semispinalis cervicis* (MSCe; MSSCe) are the craniocervical parts of the *mm. spinalis* and *semispinalis dorsi*. Both muscles are inseparable and will be discussed as one complex. The complex arises on the lateral side of the prezygapophyses of the first three thoracic (T1-T3) and last five cervical (C3-C8) vertebrae. The muscles run anterodorsad and insert at the dorsocaudal aspect of C6-C2.

\* The *mm. interarticulares* (MIART) are short intervertebral muscles occurring from C2 downwards. These muscle slips run between the ventral side of the zygapophysis near the articulation, to the slightly more dorsal aspect of the previous vertebrae.

\* The *mm. interarcuales* (MIARC) are also very short intervertebral muscles running from the neural arch of the cervical vertebrae (from C2) to the lateral side of the neural arch of the previous vertebra.

\* The *mm. interspinales* (MIS) are similar to the MIARC but run from the neural spine to the lateral aspect of the neural spine of the previous vertebrae.

### The occipito-vertebral group

\* The *m. obliquus capitis* (MOCa) is situated in the anterior neck region, laterally with respect to the MSCa and dorsally to the MLCe. Usually two distinct parts can be discerned: the MOCa magnus and the underlying MOCa inferior. The magnus part originates at the laterodorsal side of the second (partly tendinously) and the third (fleshy) cervical vertebrae. Whereas the smallest and dorsal-most part of the MOCa magnus inserts at the lateral-most aspect of the quadrate process of the parietal, the bulk of the fibres run outwards and insert at the dorsocaudal edge of the paraoccipital process. The MOCa inferior arises at the dorsal side of C2, and its fibres run anteriorly to insert at the dorsocaudal side of the postzygapophysis of the atlas (C1).

\* The *m. rectus capitis* (MRCaP) is one of the deep neck extensors and lies ventral to the MSCa, and mesial to the MOCa. The MRCaP can also be subdivided into two parts: a lateral part (*pars maior*; NISHI, 1916), originating at the dorsal side of C2 and inserting at the dorsal aspect of the supra- and exoccipital bones; and a medial part (*pars minor*; NISHI, 1916) originating at the C1-C2 junction and inserting just laterally to the ventral slip of the MSCa at the dorsal aspect of the supraoccipital bone.

### The longissimus cervico-capitis complex

The *longissimus cervico-capitis* complex is the cervical extension of the *m. longissimus dorsi*. The complex originates at the level of the last cervical and first four thoracic

vertebrae at the lateral edge of the prezygapophyses. The fibres run anteriorly and converge at the level of C5-C4 to form a strong "zwischensehne" (NISHI, 1916) that inserts at the postzygapophysis of the atlas. From the C5-C4 level upwards, several clearly individualised bundles can be identified:

\* The *m. transversalis cervicis* (MTCe) consists of two parts: a first one originating at the lateral side of the prezygapophyses of C3 and C4, and a second part originating on the ventrolateral side of C1-C3. The dorsal part inserts together with the first muscle belly of the *m. iliocostalis cervicis* at the lateral side of the postzygapophysis of the atlas. The more ventrally situated part inserts with the *m. rectus anticus*, and the *m. iliocostalis capitis* at the tuberculum speno-occipitale at the ventral side of the basi-occipital.

\* The *m. articulo-parietalis* (MAP) is situated dorsally in the neck and arises at the level of C4 on the "zwischensehne". From their origin, the fibres radiate anterolaterally and insert at the posterodorsal aspect of the quadrate process of the parietal, adjacent to the insertion of the MSCa, and dorsal to that of the MOCa.

\* The *m. transversalis capitis* (MTCa) is located dorsolaterally in the neck and originates at the "zwischensehne" at the level of C2-C6. The fibres turn outwards, converge, and insert ventral to the insertion of the MOCa at the laterocaudal edge of the paraoccipital process, and lateral of the MAP at the lateralmost edge of the posterior side of the quadrate process of the parietal.

### The rectus anticus

\* The *m. rectus anticus* (MRA) is the ventralmost neck muscle and best-developed neck flexor. It arises at the ventral sides of the processus transversi of C2-C6, and from the medial, proximal side of the third and fourth cervical rib. The fibres run anteriorly and outwards at an angle of about 45°. Laterally the fibres converge to form a strongly developed tendon that inserts at the tuberculum speno-occipitale.

### The ventral and lateral monoarticular muscles

\* The *mm. intertransversarii* (MIT): these small intervertebral muscles are situated at the deepest level of the ventrolateral side of the neck. The first MIT is the one running inbetween C1 and C2. The *m. intertransversarii* can be subdivided into two separate parts. A more superficial part runs from the caudal side of the processus transversus to the anterior side of the processus of the next vertebra, while the deeper part originates at the ventral side of the processus transversus and runs to the anteroventral side of the processus transversus of the next vertebra.

\* The *mm. atlantico-occipitales* (MAO) are two short muscles similar to the *mm. intertransversarii*, but attaching to the skull instead. The dorsal-most of the two originates at the ventral side of the atlas and runs to the tuberculum speno-occipitale; the somewhat more ventrally originating muscle inserts medial to the other MAO at the basioccipital.

### The illicostalis complex

\* The *m. illicostalis cervicis* (MICoCe) forms, together with the *m. illicostalis capitis*, the cervical extension of the *m. illicostalis dorsi* (NISHI, 1916). Both muscles of the complex are situated at the lateral side of the neck, lateroventral with respect to the *m. longissimus cervicis*. The MICoCe consists of four distinct bellies. The posterior two are the smallest and originate at the fascia dorsi at the level of C7. Both muscles insert tendinously at the diapophyses of C5 and C4. The next belly (more cranially) is somewhat bigger and originates at the dorsolateral edge of the *m. longissimus cervicis* at the level of C6. The fibres run anteroventrad and insert by means of an aponeurosis at the diapophysis of C3. The cranial-most belly is the largest, and originates in a bipartite manner at the dorsolateral edge of the *m. longissimus cervicis* at the level of C5. Both parts unite and insert tendinously at the postzygapophysis of the atlas.

\* The *m. illicostalis capitis* (MICoCa) originates at the level of C4-C3 at the dorso-lateral edge of the *m. longissimus cervicis* and inserts with the *m. longissimus capitis* at the ventral side of the basioccipital.

### The scalenus anticus

\* The *m. scalenus anticus* (MSA) originates at the hypapophyses, and the ventral aspect of the processus transversus of C1-C3. The fibres run posteriad and insert at the first cervical rib.

### The musculature associated with the pectoral girdle

\* The *m. episternocleidomastoideus* (MEM) originates at the connective tissue associated with the clavicle. The fibres curve anterodorsad around the neck and insert at the connective tissue at the posterolateral side of the parietal, just ventral to the origin of the *m. depressor mandibulae*.

\* The *m. serratus* (MS) consists of three bellies originating at the posteromedial side of the suprascapula. The fibres run anteroventrad and insert at the cervical ribs of C3 and C4.

\* The *m. levator scapulae superficialis* (MLSS) is, with the exception of the MEM, the lateral-most muscle in the cervical region. The muscle originates tendinously at the ventrolateral side of the diapophysis of the atlas. Its fibres run posterodorsad and insert at the anterolateral side of the suprascapular bone.

\* The *m. levator scapulae profundus* (MLSP) lies just ventral, and adjacent to the superficial part. Its origin is similar to that of the superficial part. The fibres run posterodorsad and insert at the ventral anterolateral side of the suprascapula, and at the dorsal side of the clavicle.

\* The *m. trapezius* (MT) originates at the lateral side of the clavicle and inserts, just dorsal to the suprascapula at the fascia dorsalis.

\* The *m. trapezius anterior* (MTA) also originates at the dorsal aspect of the clavícula. Two distinct parts can be discerned, based on differences in the insertion: the anteriormost part inserts at the lateral edge of the fascia dorsalis, just posterior to the MEM; the fibres of the more posterior part on the other hand run directly dorsad, cover the first part of the MLS, and insert at the fascia dorsalis.

## DISCUSSION

The only other study dealing with the cervical musculature in helodermatids is that of RIEPPEL (1980). A comparison of these data with ours is, however, difficult as RIEPPEL (1980) discussed only parts of the cervical system, and used a different nomenclature. For example, the longissimo cervico-capitis complex as described here is not recognised as such by RIEPPEL (1980). The most important differences are situated in the MSCa and the MRA. In the animals examined here, no slip of the MSCa running outward to the para-occipital process was present. This character was, however, used to distinguish helodermatids from other platynotan lizards (RIEPEL, 1980). Presumably this slip as described by RIEPPEL (1980) corresponds to a part of the MAP as described here. The other important difference lies in the MRA. Whereas RIEPPEL (1980; following the terminology of OELRICH, 1956) discerned two separate muscles (the mesial *m. rectus capitis anterior* and the lateral *m. longissimus capitis*), in the animals examined in the present study these two clearly form a single muscle: the fibres coming from the mesial part (= *m. rectus capitis anterior* of RIEPPEL, 1980) converge at the ventrolateral side of the neck to form one muscle (= *m. longissimus capitis* of RIEPPEL, 1980).

Despite the importance of the cervical system, the available information on neck musculature in lizards in general, is scarce, incomplete, and sometimes even erroneous. For example, in most accounts (DE VIS, 1884; JENKINS & TANNER, 1968; AVERY & TANNER, 1971) fewer muscles are described than are actually observed for closely related representatives (pers.obs.). Nevertheless, the data gathered in this study indicate that, in general, the bauplan of the cervical musculous system appears stable within closely related phylogenetic groups. For both the *Heloderma* specimens examined here, few or no inter-specific differences in neck musculature were observed. Similarly, preliminary data on agamid (*Ploceoderma stellio* (Blyth, 1854) and *Hydrosaurus amboinensis* (Kaup, 1828)) and closely related uromastycine lizards indicate a general within-group conservatism.

In lizards, the feeding process can be categorised as lingual or inertial (BRAMBLE & WAKE, 1985). In inertial feeding, prey transport is accomplished without the intervention of the tongue; instead, a backward acceleration is imparted upon the prey when it is released from the teeth. This acceleration can only be achieved by moving the head relative to the body of the animal. Clearly the neck plays a most crucial role in this respect. However, within lizards the purely kinetic inertial feeding mode has only been described for varanid and helodermatid lizards (SMITH, 1982; HERREL *et al.*, 1997a). A comparison of the musculature in *Heloderma* with that of varanids (NISHI, 1916) indicated few differences. This observation can be related to the fact that both groups of lizards include more (*Varanus*; SMITH, 1982) or less (*Heloderma*; HERREL *et al.*, 1997a) inertial components in their feeding mechanism. The fact that, in general, few differences in neck musculature



were noted in the whole group of anguimorph lizards (RIEPEL, 1980) may indicate that: (1) all anguimorphs use (at least partially) some inertial components in their feeding system or (2) the complexity of the cervical musculature is a primitive trait for the whole group and has been exapted in relation to inertial feeding in *Heloderma* and *Varanus*.

The neck muscles also play an important role during prey processing for non-inertial feeders. In all lizards examined so far, jaw opening is achieved partially by an elevation of the neurocranium, which is mediated by activity of the dorsal cervical musculature (HERREL *et al.*, 1995, 1997b; CLEUREN, pers. comm.). Similarly, during jaw closure the ventral cervical musculature can aid in biting by actively depressing the neurocranium (GANS *et al.*, 1985). Consequently, the MSca, MAP on the dorsal side, and the MRA on the ventral side of the neck are strongly developed, at least in agamid and scincid lizards (pers. obs.).

Preliminary data on other lizards (geckoes and lacertids) indicate that the evolutionary shift from a lingual-based to a predominantly inertial feeding system within lizards apparently coincides with an increase in the complexity of mainly the epaxial components of the cervical musculature. This should be tested, however, by a thorough examination of the cervical musculature in representatives of these and other lizard groups within a strict phylogenetic framework. The nomenclature of lizard neck muscles as proposed here (based on the work of NISHI, 1916), which encompasses the full complexity of the system, should enable future workers to interpret the neck musculature in an evolutionary context.

#### ACKNOWLEDGEMENTS

We would like to thank the following persons for allowing us to examine specimens in their care: B. Reynolds from the Smithsonian Institution (*H. horridum*) and E.J. Censky (*H. suspectum*) from the Carnegie Museum of Natural History. We would also like to thank J. Cleuren for allowing us to use his unpublished data on the neck musculature of *A. equestris*. All other specimens used are from a personal collection. AH is a postdoctoral fellow of the Fund for Scientific Research-Flanders Belgium (FWO-VL); Supported by FWO-grant 6.0221.96.

#### REFERENCES

- AVERY, D.F. & W.W. TANNER (1971) – Evolution of the iguanine lizards (Sauria, Iguanidae) as determined by osteological and myological characters. *Brigham Young Univ. Sci. Bull. Biol. Ser.*, **12** (3): 1-79.
- BOAS, J.E.V. (1929) – Biologisch-anatomische Studien Über den Hals der Vögel. *K. Dan. Vidensk. Selsk. Skr. Naturvidensk. Math.*, **9**, **1,3**: 101-222.
- BOCK, W.J. & C. SHEAR (1972) – A staining method for the gross dissection of vertebrate muscles. *Anat. Anz.*, **130**: 222-227.
- BRAMBLE, D & D.B. WAKE (1985) – Feeding mechanisms of lower tetrapods. In: HILDEBRAND, M. D. BRAMBLE, K. LIEM & D.B. WAKE (Eds.) *Functional vertebrate morphology*. Harvard University Press, Cambridge: 230-261.
- CLEUREN, J. & F. DE VREE (1992) – Kinematics of the jaw and hyolingual apparatus during feeding in *Caiman crocodilus*. *J. Morphol.*, **212**: 141-154.

- CLEUREN, J. (1996) – Functionele morfologie van het craniocervicaal en hyolinguaal apparaat van *Caiman crocodilus* tijdens de inertiële voedselopname. Unpublished PhD. thesis, University of Antwerp.
- DE VIS, C.W. (1884) – Myology of *Chlamydosaurus kingii*. *Proc. Linn. Soc. N.S.W.*, **1884**: 300-320.
- FREY, E. (1988) – Anatomie des Körperstammes von *Alligator mississippiensis* Daudin. *Stuttgarter Beitr. Naturk., Ser. A.*, **424**: 1-106.
- GANS, C. (1969) – Comments on inertial feeding. *Copeia*, **1969** (4): 855-857.
- GANS, C. (1992) – Why develop a neck? In: BERTHOZ, A., P.P. VIDAL & W. GRAF (Eds.) *The head-neck sensory motor system*. Oxford University Press, New York: 17-21.
- GANS, C, F. DE VREE & D. CARRIER (1985) – Usage pattern of the complex masticatory muscles in the shingleback lizard, *Trachydosaurus rugosus*: a model for muscle placement. *Am. J. Anat.*, **173**: 219-240.
- GEORGE, J.C. & R.V. SHAH (1954) – The myology of the head and neck of the common Indian pond turtle, *Lissemys punctata granosa* (Schoepff). *J. Anim. Morph. Physiol.*, **1**: 1-12.
- GEORGE, J.C. & R.V. SHAH (1955) – The myology of the head and neck of the Indian tortoise, *Testudo elegans*. *J. Anim. Morph. Physiol.*, **2**: 1-13.
- GORNIK, G.C. & C. GANS (1980) – Quantitative assay of electromyograms during mastication in domestic cats (*Felis catus*). *J. Morphol.*, **163**: 253-281.
- HERREL, A., J. CLEUREN & F. DE VREE (1995) – Prey capture in the lizard *Agama stellio*. *J. Morphol.*, **224**: 313-329.
- HERREL, A., I. WAUTERS, P. AERTS & F. DE VREE (1997a) – The mechanics of ovophagy in the beaded lizard (*Heloderma horridum*). *J. Herpetol.*, **31** (3): 383-393.
- HERREL, A., J. CLEUREN & F. DE VREE (1997b) – Quantitative analysis of jaw and hyolingual muscle activity during feeding in the lizard *Agama stellio*. *J. Exp. Biol.*, **200**: 101-115.
- HOFFSTETTER, R. & J-P. GASC (1969) – Vertebrae and ribs of modern reptiles. In: GANS, C., A.d'A BELLAIRS & T.S. PARSONS (Eds.) *Biology of the Reptilia, Vol. 1*. Academic Press, London: 201-310.
- JENKINS, R.L. & W.W. TANNER (1968) – Osteology and myology of *Phrynosoma p. platyrhinos* Girard and *Phrynosoma d. hernandesi* Girard. *Brigham Young Univ. Sci. Bull. Biol. Ser.*, **9**: 1-34.
- JOUFFROY, F.K. (1992) – Evolution of the dorsal muscles of the spine in light of their adaptation to gravity effects. In: BERTHOZ, A., P.P. VIDAL & W. GRAF (Eds.) *The head-neck sensory motor system*. Oxford University Press, New York: 22-35.
- NISHI, S. (1916) – Zur vergleichenden anatomie der eigentlichen rückenmuskeln. *Morphol. Jahrb.*, **50**: 219-247.
- OELRICH, T.M. (1956) – The anatomy of the head of *Ctenosaura pectinata* (Iguanidae). *Misc. Publ. Mus. Zool. Univ. Michigan*, **94**: 1-122.
- RICHMOND, F.J.R. & J.B. ARMSTRONG (1988) – Fiber architecture and histochemistry in the cat neck muscle, biventer cervicis. *J. Neurophysiol.*, **60**: 46-59.
- RIEPEL, O. (1980) – The phylogeny of anguimorph lizards. Basel, Birkhäuser Verlag: 86 pp.
- RINKER, G.C. (1954) – The comparative myology of the mammalian genera *Sigmodon*, *Oryzomys*, *Neotoma* (Cricetinae), with remarks on their intergeneric relationships. *Misc. Publ. Mus. Zool. Univ. Michigan*, **83**: 1-13.
- SANDERS, A. (1870) – Notes on the myology of *Platydactylus japonicus*. *Proc. Zool. Soc. London* **1870**: 413-426.
- SANDERS, A. (1872) – Notes on the myology of *Leiolepis belli*. *Proc. Zool. Soc. London*, **1872**: 154-183.

- SANDERS, A. (1874) – On the myology of *Phrynosoma coronatum*. *Proc. Zool. Soc. London*, **1874**: 71-89.
- SCANLON, T.C. (1982) – Anatomy of the neck of the Western painted turtle (*Chrysemys picta belli* Gray; Reptilia, Testudinata). Unpublished PhD. thesis, University of Michigan.
- SEIDEL, R. (1978) – The somatic musculature of the cervical and occipital regions of *Alligator mississippiensis*. Unpublished PhD thesis, City University of New-York, New York.
- SHAH, R.V. (1963) – The neck musculature of a cryptodire (*Deirochelys*) and a pleurodire (*Chelodina*) compared. *Bull. Mus. Comp. Zool.*, **129**: 343-368.
- SMITH, K.K. (1982) – An electromyographic study of the function of the jaw adducting muscles in *Varanus exanthematicus* (Varanidae). *J. Morphol.*, **173**: 137-158.
- VALLOIS, H.V. (1922) – Les transformations de la musculature de l'épisme chez les vertébrés. *Arch. Morph. Gen. Exper.*, **13**: 1-538.
- VANDEN BERGE, J.C. & G. ZWEERS (1993) – Myologia. In: BAUMEL, J.J. (Ed.) *Handbook of avian anatomy: Nomina anatomica avium*. Nuttall Ornithological Club, Cambridge: 189-247.
- ZWEERS, G. (1982) – Pecking of the pigeon (*Columba livia*). *Behaviour*, **81**: 174-230.
- ZWEERS, G., R. BOUT & J. HEIDWEILLER (1994) – Motor organization of the avian head-neck system. In DAVIES, M.N.O. & P.R. GREEN (Eds.) *Perception and motor control in birds*. Springer, Berlin: 201-221.