

## CHAPTER XX-2

**THE SPY VI CHILD****Isabelle CREVECOEUR, Hélène ROUGIER & Bruno MAUREILLE****Abstract**

*The sorting of the RBINS faunal collections from the 1952-1954 excavation campaigns of F. Twiesselmann at Spy led to the discovery of the remains of a Neandertal child, Spy VI. This individual is represented by two mandibular corpus fragments (Spy 194a, left, and Spy 646a, right), the left one being the most complete; both preserve the mental foramen. Four deciduous teeth have been associated to these mandibular remains: three incisors and one canine. The lower left canine (Spy 645a) conjoins with the corresponding socket in the left part of the mandible. The three incisors are related to the same Neandertal child based on their morphological and metrical characteristics as well as their formation stages. The two central incisors (Spy 589a, upper right, and Spy 592a, lower left) show the same degree of root formation whereas the lower right lateral incisor (Spy 594a) has a slightly less complete root. Following extant standards, these dental development stages point to an age-at-death of about one and a half years. The mandibular fragments and the dental remains are compared metrically and morphologically to a sample of immature Neandertal mandibles and deciduous teeth as well as to European Upper Palaeolithic, Mosan Neolithic and recent modern human groups. The <sup>14</sup>C direct dating of Spy VI confirms the recent age previously found for the two Neandertal adults, but does not exclude the possibility that Spy VI is younger than Spy I and Spy II.*

**INTRODUCTION**

During the exhaustive sorting (2004-2006) of the faunal collections coming from the official and private excavations campaigns led at Spy, new Neandertal remains were identified. Six of them (two mandibular fragments and four teeth) can be attributed to an immature individual designated Spy VI. These new remains of a Neandertal child all come from the faunal collection from the 1952-1954 excavations campaigns of F. Twiesselmann, which he carried out on the slope facing the cave entrance (Figure 1).

The immature Neandertal mandibular fragments and the four Neandertal deciduous teeth come from distant square-meter quadrants and different depths of the slope deposits (from the top soil to the ZJM layer, a difference of more than 1.12 m in depth; see Pirson *et al.*, volume 1: chapter VI).

Their identification and isolation from the rest of the immature Neolithic material was facilitated by the good preservation state of the fragments demonstrating their clear heterogeneity in size and morphology compared to the rest of

the Neolithic human specimens (deciduous teeth, n = 49; immature mandibular fragments, n = 4). Although the Neandertal remains were scattered throughout the slope deposit area, the secondary anatomical connection between the left mandibular corpus fragment (Spy 194a) and the left deciduous lower canine (Spy 645a) (the root of the tooth fits perfectly within the preserved half of the corresponding alveolar cavity on Spy 194a) and the coherence between the maturational stages of the deciduous teeth are consistent with the attribution to the same individual.

Only few immature Neandertal specimens have been discovered so far. The importance of the Spy VI discovery is proportional to the scarcity of fossils of the same age-at-death. Immature Neandertal remains provide essential information regarding the emergence, development and expression of Neandertal derived traits during growth, all the more so that early ontogenetic divergence in cranial and mandibular shape between Neandertals and modern humans seems to arise early during development and to be maintained throughout postnatal growth (e.g. Tillier, 1989; Rak *et al.*, 1994; Ponce de León & Zollikofer, 2001; Bastir *et al.*, 2007).

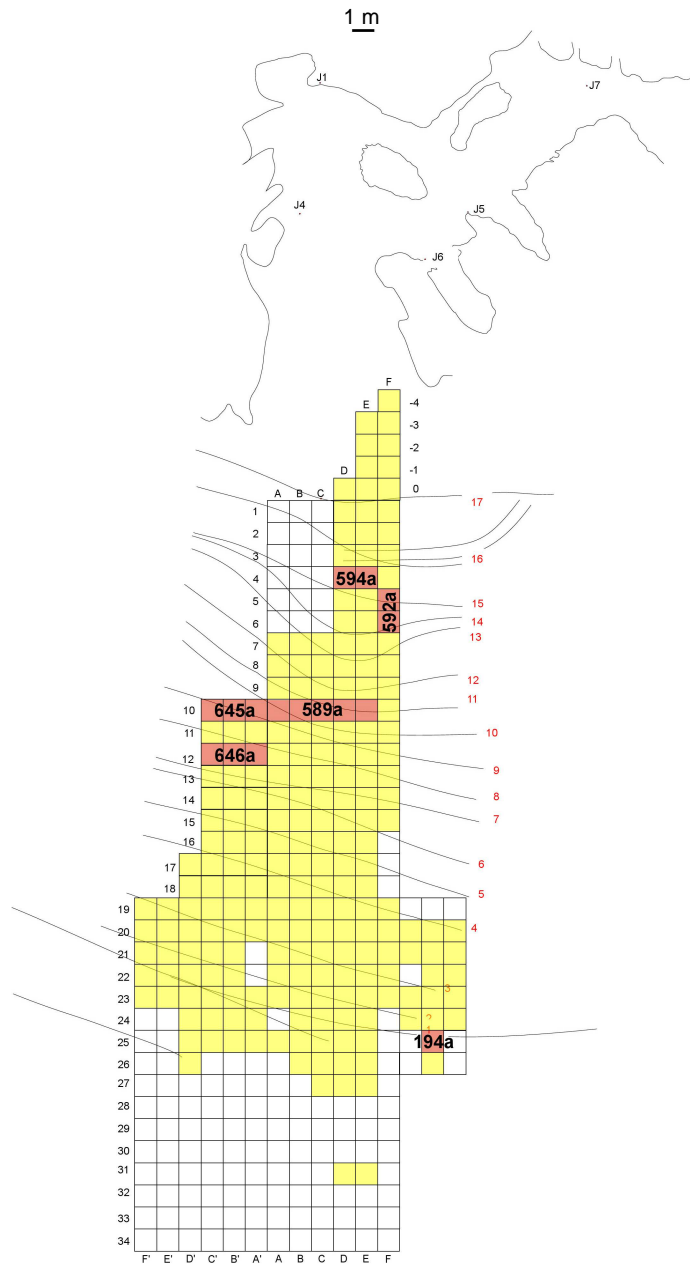


Figure 1. Map of the slope area in front of the Spy cave terrace excavated by F. Twiesselmann (1952-1954) and showing the location where the newly identified immature Neandertal remains were found.

Here we present a comparative morphometric study of the mandibular corpus and the deciduous teeth of Spy VI with samples of Neandertals, European Upper Palaeolithic modern humans, Mosan Neolithics and recent humans. The position of this specimen within the Neandertal variability is discussed as well as its association with the two adult Neandertals (Spy I and II) given the results of the direct radiocarbon dating of the specimen.

## MATERIAL AND METHODS

The Neandertal comparative sample (NEAND) includes mandibles and deciduous teeth from European and Asian specimens: Amud 7, Archi 1, Barakai 1, Bau de l'Aubesier 8, Baume Néron 2, Châteauneuf 1, Combe-Grenal 1, Dederiyeh 1 & 2, Engis 2, Gibraltar 2, Hortus 2, Il Molare 1, Kebara 1, 4 & 15, Krapina (KDP-1, KDP-2, KDP-7, KDP-8 & KDP-22), La Fer-

rassie 8, Las Palomas 49, Le Lazaret 2, Le Fate 2, Le Portel 21 & 28, Les Cèdres 1, Malarnaud 1, Neuessing 1, Pech de l'Azé 1, Pié-Lombard 1, Rigabe 1, Roc de Marsal 1, San Bernardino 5, Shanidar 7, Suard 5-14 & 37, Subalyuk 2, and Teshik-Tash 1. A European Upper Palaeolithic modern human sample (EUP) was also used in metric comparisons of the deciduous dental remains. The EUP sample was composed of teeth from Abri Pataud 7, Arene Candide 6 & 8, Bombin 1, Dolní Věstonice 36/1 & 36/5, Gazel 1, Grotte des Enfants 1 & 2, Lafaye 25, Lagar Velho 1, La Madeleine 4, Le Figuier 1, Les Peyrugues 1 & 8, Maritza 2, Pavlov 17 & 18, Rochereil 1, Saint-Germain 05, 07 & 09, Troubat 1 and Vado All'Arancio 2. Data for the Neandertal and Upper Palaeolithic samples were derived from our own observations of the fossils and from published dental measurements compiled by B. Maureille and D. Henry-Gambier (pers. com.; see also Henry-Gambier *et al.*, 2004).

Mandibles of immature Mosan Neolithic specimens (NEOM) have been included in our analysis. They come from Hastière (Petite Caverne, Caverne M and Trou Garçon) and Maurenne (Caverne de la Cave), and are stored at the RBINS.

Finally, the recent human sample (RMH) used to compare crown diameters included European, Asian and African specimens compiled by B. Maureille (see also Maureille, 2001).

Adjusted Z-Scores (Houët in Maureille *et al.*, 2001) were computed to compare the dimensions of the Spy VI teeth to the means and standard deviations of the comparative groups.

## MORPHOLOGICAL AND METRICAL DESCRIPTION

### Mandibular corpus

Spy VI is represented by two fragments of mandibular corpus (Spy 194a, left, and Spy 646a, right; Figure 2), both preserving the mental foramen. The left part of the mandible (Spy 194a) is the most complete, with a total length of 39.35 mm. It extends from the decidu-

ous canine socket to the mesial half of the permanent first molar crypt. At the mesial extremity of the fragment, the distal half of the permanent canine crypt is visible under the Lm1 socket. The right fragment (Spy 646a) is limited to the socket of the deciduous first molar and the eroded internal face of the corpus.

The morphology and position of the mental foramen are identical on both mandibular fragments. The foramen is single and situated under the deciduous first molar socket, below the junction between the two roots of the tooth. The shape of the foramen is oval with a smooth supero-mesial border (width = 3.1 mm; height = 1.9 mm). According to Coqueugniot (2000), a posterior position of the mental foramen can be observed in Neandertal specimens before the development of the permanent dentition. The frequency of Neandertals with a foramen under Lm1-Lm2 is higher than that observed among modern humans. However, considering the results of L'Engle Williams & Krovitz (2004), this feature may provide less taxonomic information than previously thought. The moderately mesial position of the Spy VI mental foramen (under Lm1) is nevertheless exhibited by 54 % of Neandertal children (Coqueugniot, 2000) and is present in specimens of the same age class (e.g. Palomas 49, Dederiyeh 1 & 2). Below the mental foramen, a *tuberculus marginalis anterior* is visible on Spy 194a at the junction between the lateral and inferior faces of the corpus. A *tuberculus marginalis posterior* is also present 8.6 mm distally. Its projection is slightly more expressed than that of the anterior tubercle. The *prominencia lateralis* is visible on Spy 194a, but no individualisation of a lateral marginal torus is present. The prominence becomes blurred at the level of the deciduous first molar.

The internal face of the corpus is preserved only on Spy 194a. The oblique line (*linea mylohyoidea*) is strongly developed; it is straight and oblique from the upper margin of the permanent first molar alveolus to the bottom of the corpus under the deciduous canine. The line divides the corpus into a deep sublingual fossa just below the deciduous first molar and a poorly defined submandibular fossa. The surface of the latter is nearly flat and inclined toward the inferior face of the corpus.

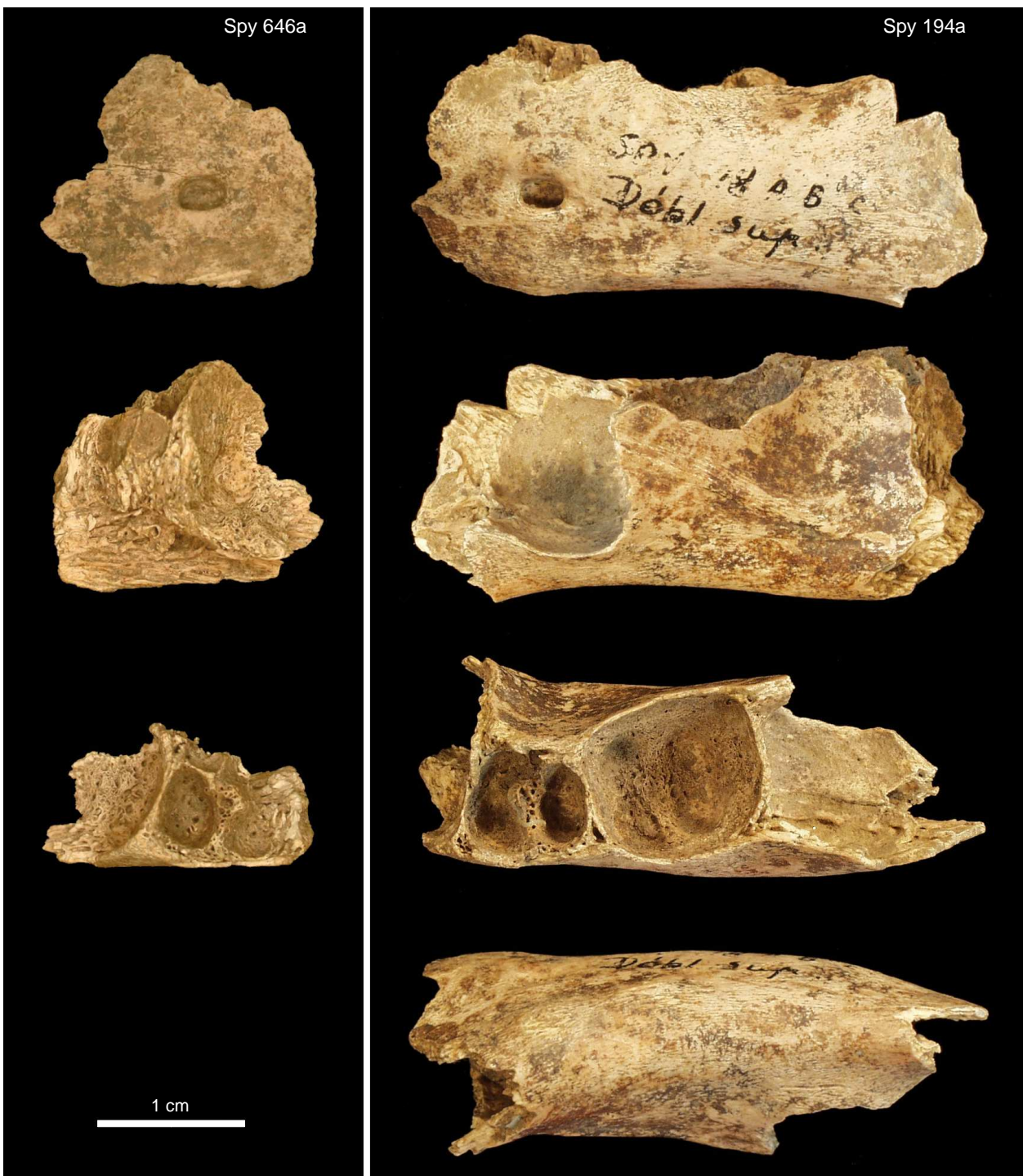


Figure 2. Preserved mandibular fragments of Spy VI. Sp 646a: right mandibular corpus fragment; Spy 194a: left mandibular corpus fragment. From top to bottom, the fragments are presented in lateral, medial, superior and inferior views. Scale = 1cm.

The dimensions of the Spy 194a mandibular fragment are given in Table 1. According to Walker *et al.* (2008), the breadth of the mandibular corpus differs significantly between Neandertal

and modern human adult specimens. This observation also appears to be true for immature mandibles (Mallegni & Trinkaus, 1997). The breadth of the mandibular corpus of Spy 194a at the level

	<i>Mental foramen</i>	<i>Lm1 &amp; Lm2</i>	<i>Lm2 &amp; LM1</i>
Height (mm)	17.31	17.43	14.25
Breadth (mm)	10.60	11.33	13.52
Robustness Index	61.24	65.00	94.88

Table 1. Height and breadth of the Spy 194a mandibular corpus at the level of the mental foramen [M69(1) & M69(3)], between the alveoli of the deciduous first and second molars (Lm1 & Lm2) and between the alveoli of the deciduous second and permanent first molars (Lm2 & LM1).

The Robustness Index refers to the breadth / height ratio at each level.

of the mental foramen [M69(3), according to Bräuer, 1988] was compared to a sample of Neandertals and Mosan Neolithics split into four age classes (Figure 3). These age classes are defined on the basis of the maturation stages of the two deciduous molars and of the permanent first molar (see Figure 3 caption). In the case of Spy VI, we can rely only on the sockets of these teeth to determine the age class of the mandibular fragment. Although it is not possible to state a definite developmental stage for both the deciduous

and the first permanent molars, the root sockets were moulded in order to give an estimation of the development of the deciduous molar roots. The moulds indicate that the Lm1 is in occlusion and that the Lm2 is in eruption, placing the Spy VI fragment in the second age class. The thickness of the Spy VI mandibular corpus at the level of the mental foramen (10.6 mm) is closest to the value of the Dederiyeh 1 individual (Figure 3), and there is a clear separation between the Neandertal and Neolithic values within each age group.

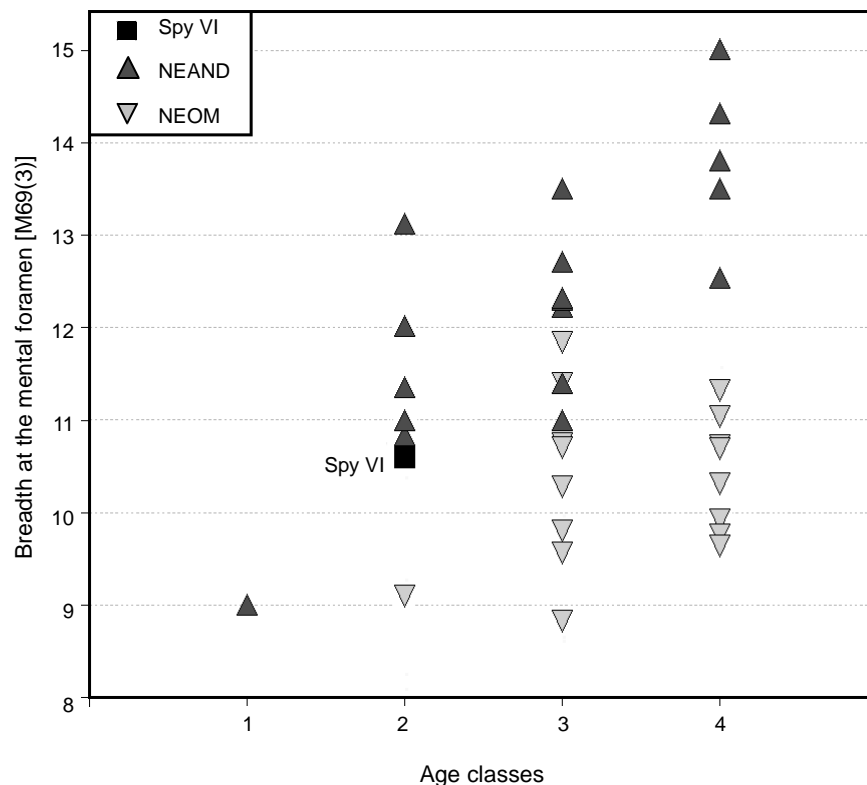


Figure 3. Breadth of the mandibular corpus at the level of the mental foramen [M69(3) after Bräuer, 1988] for Spy VI, Neandertals (NEAND) and Mosan Neolithics (NEOM) divided in four dental maturation stages. Age classes are as follows: (1) Lm1 and Lm2 not erupted; (2) Lm1 erupted and Lm2 erupting; (3) Lm2 erupted; (4) LM1 erupting.

### Deciduous teeth

Four deciduous teeth are associated with the mandibular fragments of Spy VI. They exhibit morphological and metrical characteristics present among immature Neandertal specimens. These four teeth were easily isolated from the other deciduous incisors and canines from Spy (n = 8), which may be of Neolithic age.

#### *Upper central incisor (Ui1)*

The right maxillary central incisor (Spy 589a) is very well preserved (Figure 4). Only a small fragment of enamel (3 mm wide and 0.3 mm thick) is chipped off at the cervix of the tooth on the lingual surface. The root length is complete but its apex is partly broken. The stage of development of this tooth may then be either A½ or Ac in the coding system of Moorrees *et al.* (1963a, 1963b).

The root is flattened labio-lingually. It is wide, with a maximum mesio-distal diameter of 6.6 mm and a root-neck index (ratio of the

mesio-distal and vestibulo-lingual diameters of the root at the level of the neck) of 135. The distal third of the root is lingually deviated as on Les Cèdres 1.

The crown shows a small wear facet on the mesial part of the occlusal surface. The dentine is slightly exposed [Molnar (1971) stage 2]. The convexity of the labial surface is well marked in both the mesio-distal (ASUDAS grade 4; Turner *et al.*, 1991) and vertical directions. The lateral edges of the labial surface are thickened and form marginal ridges that extend at an angle close to 90° to the mesio-distal axis of the crown, forming the shovel-shaped morphology of the lingual face (ASUDAS grade 3) common among Neandertal specimens (e.g. Tillier, 1983; Trinkaus, 1983). A moderate lingual tubercle is developed in the upper part of the lingual surface of the crown, which is concave below the tubercle (ASUDAS grade 1). The crown is slightly asymmetrical in labial and lingual view, with its distal border more rounded and distally projecting than the mesial side.

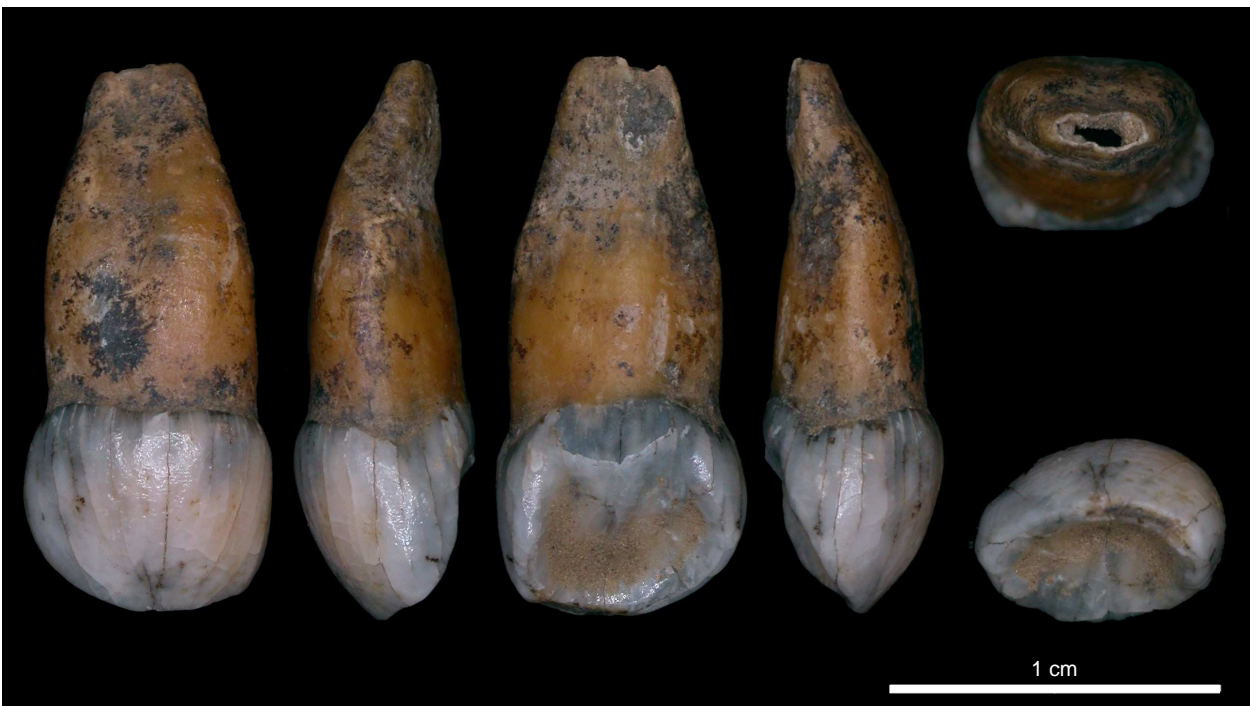

Figure 4. The right deciduous upper central incisor (Ui1) of Spy VI, Spy 589a. From left to right: views of the labial, mesial, lingual, distal, apical (top), and occlusal (bottom) sides.

*Lower incisors (Li1 and Li2)*

The left deciduous central incisor (Spy 592a) is well preserved (Figure 5). Its root is straight and complete and has a triangular cross-sectional shape. The total length of the root is 9.1 mm, and the very tip of the apex is still open and the apical walls converging (corresponding to stage A $\frac{1}{2}$  of Moorrees *et al.*, 1963b). The maximum mesio-distal width of the root is 4 mm and the root-neck index is 97.8.

The crown is slightly worn on the occlusal surface [Molnar (1971) stage 2]. Two small fragments of enamel (< 1 mm) are missing: one on the labial side of the crown at the junction with the occlusal face, and the other on the lingual side of the crown at the root-neck junction. The labial surface is evenly and gently convex. The lingual surface is flat vertically. Two small ridges mark the lateral edges of this face (ASUDAS grade 1). The crown is slightly asymmetric in labial and lingual view; this asymmetry is related to the slight distal projection of the distal side.

The right deciduous lateral incisor (Spy 594a) is complete (Figure 6). Its root is not fully formed, with the apex still open and the apical

edges parallel (close to grade R $\frac{3}{4}$  of Moorrees *et al.*, 1963b). The root is triangular in cross-section but more flattened transversally than the root of the central incisor Spy 592a. A shallow sulcus is visible on the lower half of the distal face of the root. The root has a maximum breadth of 3.9 mm and a root-neck index of 84.4. The crown shape of the right lateral incisor is strongly asymmetric with an important distal projection of its distal edge. The labial surface of the crown is evenly convex, while the lingual face is slightly concave with a very moderate vertical ridge through the middle. No wear surface is visible on the occlusal side of the tooth [Molnar (1971) stage 1].

*Lower canine (Lc)*

The left deciduous lower canine (Spy 645a) is not fully formed (Figure 7); its root has achieved approximately half of its total length, but the root length is slightly less than the crown height (stage R $\frac{1}{2}$  of Moorrees *et al.*, 1963a). The shape of the root is roughly triangular with a root-neck index of 97.9.

The crown is well preserved with only a small break in the enamel on the supero-mesial part of the labial surface. This face exhibits a




Figure 5. The left deciduous lower central incisor (Li1) of Spy VI, Spy 592a. From left to right: views of the labial, mesial, lingual, distal, occlusal (top), and apical (bottom) sides.

well-marked transverse convexity. The lingual side is concave; as in Pech de l'Azé 1 (Legoux, 1970), there is no central crest. The mesial border of the crown turns lingually, forming a slight ridge on the

lingual surface. The distal side of the canine crown is longer and more distally projected than the mesial side. The distal border is not evenly convex distally but forms a clear angle at 1/3 of the



Figure 6. The right deciduous lower lateral incisor (Li2) of Spy VI, Spy 594a. From left to right: views of the labial, mesial, lingual, distal, occlusal (top), and apical (bottom) sides.




Figure 7. The left deciduous lower canine (Lc) of Spy VI, Spy 645a. From left to right: views of the labial, mesial, lingual, distal, occlusal (top) and apical (bottom) sides.



height of the crown. At the same height, a small notch is present on both lateral marginal crests, the distal notch being more pronounced than the mesial one. Beneath this notch, a small tubercle is present on the lingual surface at the junction with the distal edge of the canine. There is no wear facet on the occlusal side of the crown [Molnar (1971) stage 1], and the tooth was obviously not yet in occlusion upon the death of Spy VI.

#### *Dental biometric comparisons*

The mesio-distal (MD) and labio-lingual or vestibulo-lingual (VL) diameters of the crowns are listed in Table 2 and compared to the means and standard deviations of the comparative groups. Figure 8 illustrates the Adjusted Z-Scores of the Spy VI dental diameters compared to the variation among the Neandertal, European Upper Palaeolithic and extant modern human samples. With the exception of the vestibulo-lingual dimensions of Spy 589a and of Spy 645a, all the diameters fall outside the 95 % confidence interval of the extant variation. The differences in dimensions are less distinct when compared with the European Upper Palaeolithic modern sample. With the exception of the mandibular central incisor dimensions, the diameters of the Spy VI teeth fall in the variation range of the EUP sample.

Nevertheless, the MD and VL diameters of the Spy VI teeth are closer to the means of the Neandertal range of variation. Only the breadth of the maxillary central incisor lies in the lowest part of the Neandertal range of variation. However, it is worth noting that this is a conservative measurement given the loss of a small chip of enamel on the lingual side of the crown. The thickness of this flake is close to 0.3 mm. Adding this value to the measured VL dimension would position this diameter (589a-VL) at the same level as the MD diameter in Figure 8.

#### **DETERMINATION OF THE AGE-AT-DEATH**

The timing of dental development in Neandertals has been found to be either faster (e.g. Ramirez Rozzi & Bermúdez de Castro, 2004; Smith *et al.*, 2007, 2008) or comparable to that of modern humans (e.g. Guatelli-Steinberg *et al.*, 2005; Macchiarelli *et al.*, 2006), with possible differences between the tooth types (Smith *et al.*, 2007; see also Guatelli-Steinberg, 2009). Accordingly, modern human standards are likely imperfect when used for Neandertals, and might bias the age assessment towards an older age.

		<i>Ui1</i>		<i>Li1</i>		<i>Li2</i>		<i>Lc</i>	
		<i>MD</i>	<i>VL</i>	<i>MD</i>	<i>VL</i>	<i>MD</i>	<i>VL</i>	<i>MD</i>	<i>VL</i>
SPY VI		7.44	5.47	5.11	4.76	5.49	5.06	6.73	5.75
NEAND	m	7.69	6.13	4.94	4.66	5.44	4.85	6.81	6.04
	s	0.36	0.35	0.33	0.25	0.52	0.25	0.57	0.52
	n	23	23	17	17	16	15	22	23
EUP	m	7.20	5.42	4.37	3.96	5.11	4.58	6.28	5.99
	s	0.52	0.35	0.22	0.28	0.32	0.30	0.53	0.35
	n	19	18	13	12	16	18	19	21
RMH	m	6.24	4.87	3.97	3.69	4.50	4.14	5.76	5.34
	s	0.46	0.35	0.36	0.34	0.47	0.37	0.40	0.42
	n	47	47	54	58	63	62	77	76

Table 2. Dimensions (in mm) of the teeth of Spy VI compared with the means (m), standard deviations (s) and sizes (n) of the comparative samples. MD = mesio-distal diameter (M81 after Bräuer, 1988); VL = vestibulo-lingual diameter [M81(1)]; NEAND = Neandertals; EUP = European Upper Palaeolithic modern humans; RMH = Recent modern humans.

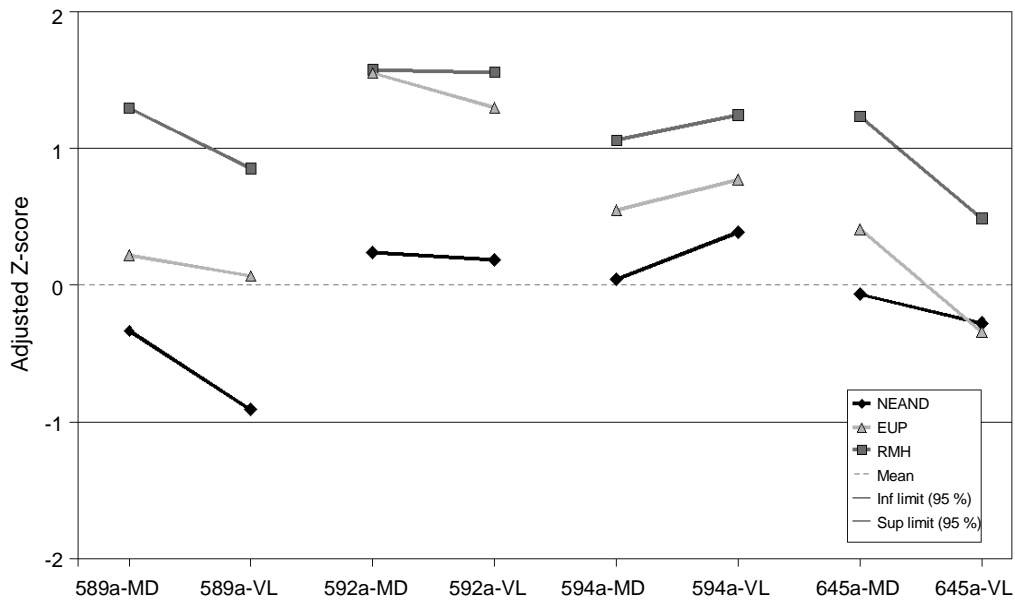


Figure 8. Adjusted Z-scores of the tooth dimensions of Spy VI compared to the Neandertal (NEAND), European Upper Palaeolithic modern human (EUP) and extant modern human (RMH) ranges of variation. A null value corresponds to the mean and the interval between  $-1$  and  $+1$  includes the 95 % confidence interval of the reference sample so that a specimen value outside of this range has a  $P < 0.05$  of belonging to this reference sample. MD = mesio-distal diameter; VL = vestibulo-lingual diameter.

Based on the extant modern human standards established by Moorrees *et al.* (1963a), the dental development stage of the deciduous canine (stage R $\frac{1}{2}$ ) indicated an age-at-death of about  $16 \pm 6$  months for the Spy VI child.

This estimation is consistent with our estimation of the stages of root formation of the deciduous molars based on the moulds of the inner space of the sockets with direct casts and on the  $\mu$ -CT data even if this method does not allow us to give a secure stage of development of their roots.

## DISCUSSION AND CONCLUSIONS

The discovery of Spy VI enriches a small corpus of immature Neandertal individuals from one to two years old (Rak *et al.*, 1994; Akazawa & Muhsen, 2002; Walker *et al.*, 2008). The morphological description and study of this specimen clearly demonstrate the presence of well-developed Neandertal characteristics early in life. Our results highlight several aspects of mandibular and dental ontogeny in Neandertal children. The

mandibular fragments of Spy VI possess a well-developed anterior and posterior *tuberculus marginalis*. The frequency of this structure is significantly higher among immature Neandertal specimens than in modern human specimens (Mallegni & Trinkaus, 1997). The breadth of the Spy VI mandibular corpus places it within the range of variation of other Neandertal mandibles of the same developmental age and at or above the upper limit of the recent human distribution. This observation confirms the assumption that immature Neandertal mandibles are generally more robust than those of recent humans (Walker *et al.*, 2008) at ages as early as one to two years old.

The four deciduous teeth show a morphometrical pattern similar to that of other known Neandertal deciduous teeth. The maxillary incisor is shovel-shaped and its labial face presents a strong mesio-distal convexity. The dimensions of the deciduous teeth are at the upper limit of or outside the recent human range of variation.

However, the scarcity of young Neandertal individuals limits our ability to evaluate tem-

poral and geographical morphometric variation as Rosas *et al.* (2006) have done for adult Neandertals. Although Spy VI clearly aligns with known Neandertal variation in the morphology and dimensions of its mandibular and dental remains, the deciduous canine possesses a crown morphology lacking a central crest, which is uncommon among immature Neandertals and only shared by Pech de l'Azé 1. The presence of unique features on Spy VI is also confirmed by the analyses of its dental tissue proportions (Crevecoeur *et al.*, 2010; Bayle & Macchiarelli, this volume: chapter XX-3). These observations underline the importance of this specimen to improve our knowledge about immature Neandertal variability.

As discussed above, there is strong evidence for the association of the newly identified Neandertal mandibular and dental remains with the same individual, Spy VI. Figure 9 presents a reconstruction of the Spy VI mandible with its three lower deciduous teeth. The distances between the dental remains and the bone fragments were evaluated using the Suard 37 mandible, which belongs to a Neandertal individual of similar dental development stage (Teilhol, 2001).

Regarding the *in situ* position of the Spy VI child in Spy cave, it may have been originally located on the terrace of the site and later became mixed with the backdirt of the nineteenth century excavations. This interpretation is suggested by the fact that several bones and teeth belonging to the Spy I and II adults, not identified *in situ*, were also found in the slope deposits. It is not possible to infer intentional character of the deposition of Spy VI due to the lack of field data and the fact that slope deposits at the site have not been extensively excavated, leaving open the question of whether other remains attributable to the Spy VI child are or were present at the site.

The discovery of the unvarnished bones and teeth attributed to Spy VI allowed us to

carry out direct radiocarbon dating of the specimen (Crevecoeur *et al.*, 2010; Semal *et al.*, volume 1: chapter XVI). The dates obtained on the small mandibular fragment Spy 646a and the upper central incisor Spy 589a confirmed the Palaeolithic age of the specimen (32,970 ± 200, -190 BP [GrA-32627]; 34,700 ± 550 BP [OxA-17977]; 33,950 ± 550 BP [OxA-21610]). Only the first measurement from Oxford falls within two standard deviations of the oldest dates obtained for the Spy adult Neandertals (Semal *et al.*, volume 1: chapter XVI). Based on the radiocarbon dating results, contemporaneity between Spy VI, Spy I and Spy II is possible but not established. We cannot exclude the possibility that Spy VI is younger than Spy I and Spy II. However, the direct dating of the specimen at about 33 - 34 ky BP provides clear evidence of the late persistence of Neandertals in northwestern Europe.

## ACKNOWLEDGEMENTS

We are grateful to the institutions that funded the TNT (The Neanderthal Tools, IST 6th framework), Spy Action 1 (Research project MO/36/012, Belgian Science Policy), and MARS (IST project I2/2F/212, Belgian Science Policy) projects, which provided the opportunity to perform multidisciplinary research on the Spy cave collections and to demonstrate their importance. The Spy dating program was funded by the FRS-FNRS through a grant to Anne Hauzeur (2005-2006/1.5.287). We also thank the Aquitaine Region for funding through the project “*Transitions, d'une société à l'autre: processus d'adaptation et de peuplements*” (Volet recherche, région aquitaine, convention 20051403003AB). We are grateful to L. Cowgill, University of Missouri, Columbia, for helping us to build up the comparative database, to D. Henry-Gambier, UMR 5199-PACEA, for allowing us to use her comparative database, to J.-F. Tournepiche, *Musée d'Angoulême*, for access to the Suard 37 fossil, and to A.-M. Tillier, UMR 5199-PACEA, for constructive discussions on the morphology of Spy VI.

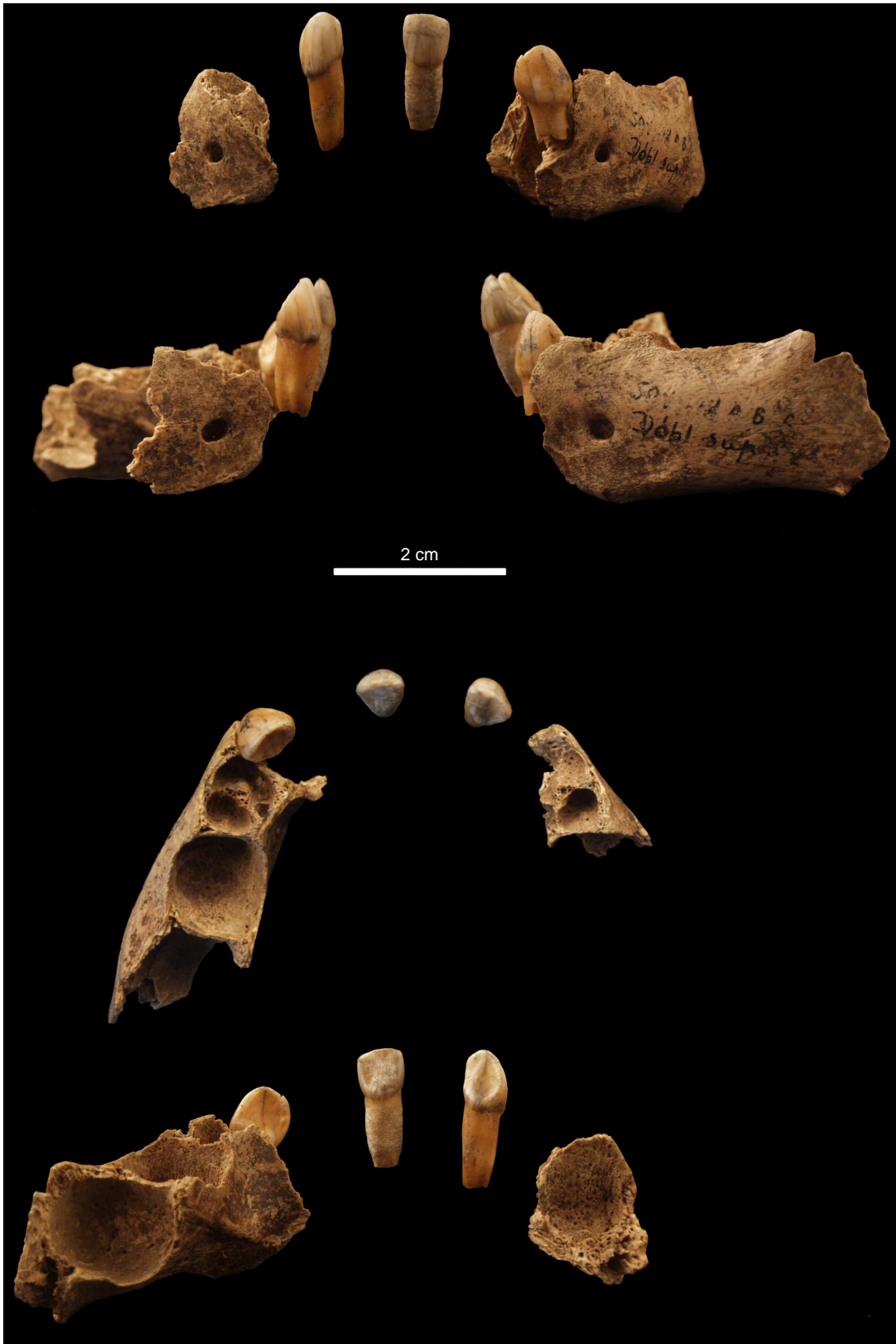

Figure 9. Reassembly of the mandibular fragments and deciduous lower teeth of Spy VI.  
From top to bottom: anterior, lateral, superior and posterior views.

**BIBLIOGRAPHY**

- AKAZAWA T. & MUHESEN S., 2002. *Neanderthal Burials. Excavations of the Dederiyeh Cave, Afrin, Syria*. Auckland, KW Publications: 394 p.
- BASTIR M., O'HIGGINS P. & ROSAS A., 2007. Facial ontogeny in Neanderthals and modern humans. *Proceedings of the Royal Society B*, **274**: 1125-1132.
- BRÄUER G., 1988. Osteometrie. In: R. KNUSSMANN (ed.), *Anthropologie: Handbuch der vergleichenden Biologie des Menschen*, Band 1. Stuttgart, Gustav Fischer: 160-232.
- COQUEUGNIOT H., 2000. La position du foramen mentonnier chez l'enfant: révision ontogénétique et phylogénétique. *Bulletins et Mémoires de la Société d'Anthropologie de Paris*, **12** (3-4): 227-246.
- CREVECOEUR I., BAYLE P., ROUGIER H., MAUREILLE B., HIGHAM T., VAN DER PLICHT J., DE CLERCK N. & SEMAL P., 2010. The Spy VI child: a newly discovered Neandertal infant. *Journal of Human Evolution*, **59** (6): 641-656.
- GUATELLI-STEINBERG D., 2009. Recent studies of dental development in Neandertals: Implications for Neandertal life histories. *Evolutionary Anthropology*, **18**: 9-20.
- GUATELLI-STEINBERG D., REID D. J., BISHOP T. A. & LARSEN C. S., 2005. Anterior tooth growth periods in Neandertals were comparable to those of modern humans. *Proceedings of the National Academy of Sciences USA*, **102**: 14197-14202.
- HENRY-GAMBIER D., MAUREILLE B. & WHITE R., 2004. Vestiges humains des niveaux de l'Aurignacien ancien du site de Brassempouy (Landes). *Bulletins et Mémoires de la Société d'Anthropologie de Paris*, **16** (1-2): 49-88.
- LEGOUX P., 1970. Étude odontologique de l'enfant néandertalien du Pech-de-l'Azé. In: F. FEREMBACH, P. LEGOUX, R. RENART, R. EMPEREUR-BUISSON & E. VLČEK (ed.), *L'enfant du Pech-de-l'Azé*. Archives de l'Institut de Paléontologie Humaine, Mémoire **33**: 53-148.
- L'ENGLE WILLIAMS F. & KROVITZ G. E., 2004. Ontogenetic migration of the mental foramen in Neandertals and modern humans. *Journal of Human Evolution*, **47** (4): 199-219.
- MACCHIARELLI R., BONDIOLI L., DEBÉNATH A., MAZURIER A., TOURNEPICHE J.-F., BIRCH W. & DEAN C., 2006. How Neanderthal molar teeth grew. *Nature*, **444**: 748-751.
- MALLEGNI F. & TRINKAUS E., 1997. A reconsideration of the Archi 1 Neandertal mandible. *Journal of Human Evolution*, **33** (6): 651-668.
- MAUREILLE B., 2001 (unpublished). *Variabilité dans le genre Homo: les mensurations des couronnes dentaires déciduales et permanentes. Synthèse de l'activité scientifique pour l'obtention de l'habilitation à diriger des recherches*. Talence, UMR 5809, Laboratoire d'Anthropologie des populations du Passé, Université Bordeaux 1, **I** (texte): 168 p., **II** (annexe): 124 p.
- MAUREILLE B., ROUGIER H., HOUËT F. & VANDERMEERSCH B., 2001. Les dents inférieures du Néandertalien Regourdou 1 (site de Regourdou, commune de Montignac, Dordogne): Analyses métriques et comparatives. *Paléo*, **13**: 183-200.
- MOLNAR S., 1971. Human Tooth Wear, Tooth Function and Cultural Variability. *American Journal of Physical Anthropology*, **34** (2): 175-190.
- MOORREES C. F. A., FANNING E. A. & HUNT E. E. JR., 1963a. Formation and resorption of three deciduous teeth in children. *American Journal of Physical Anthropology*, **21** (2): 205-213.
- MOORREES C. F. A., FANNING E. A. & HUNT E. E. JR., 1963b. Age variation of formation stages for ten permanent teeth. *Journal of Dental Research*, **42**: 1490-1502.
- PONCE DE LEÓN M. S. & ZOLLIKOFER C. P. E., 2001. Neanderthal cranial ontogeny and its implications for late hominid diversity. *Nature*, **412**: 534-538.
- RAK Y., KIMBEL W. H. & HOVERS E., 1994. A Neandertal infant from Amud Cave, Israel. *Journal of Human Evolution*, **26** (4): 313-324.
- RAMIREZ ROZZI F. V. & BERMÚDEZ DE CASTRO J. M., 2004. Surprisingly rapid growth in Neandertals. *Nature*, **428**: 936-939.
- ROSAS A., MARTÍNEZ-MAZA C., BASTIR M., GARCÍA-TABERNEIRO A., LALUEZA-FOX C., HUGUET R., ORTIZ J. E., JULIÀ R., SOLER V., DE TORRES T., MARTÍNEZ E., CAÑAVÉRAS

- J. C., SÁNCHEZ-MORAL S., CUEZVA S., LARIO J., SANTAMARÍA D., DE LA RASILLA M. & FORTEA J., 2006. Paleobiology and comparative morphology of a Neandertal sample from El Sidrón, Asturias, Spain. *Proceedings of the National Academy of Sciences USA*, **103**: 19266-19271.
- SMITH T. M., HARVATI K., OLEJNICZAK A. J., REID D. J., HUBLIN J.-J. & PANAGOPOULOU E., 2008. Brief communication: Dental development and enamel thickness in the Lakonis Neanderthal molar. *American Journal of Physical Anthropology*, **138** (1): 112-118.
- SMITH T. M., TOUSSAINT M., REID D. J., OLEJNICZAK A. J. & HUBLIN J.-J., 2007. Rapid dental development in a Middle Paleolithic Belgian Neanderthal. *Proceedings of the National Academy of Sciences USA*, **104**: 20220-20225.
- TEILHOL V., 2001. *Contribution à l'étude individuelle des ossements d'enfants de La Chaise de Vouthon (Charente, France): approche paléodémographique, paléoethnologique, aspect morphologique et étude métrique. Place phylogénique des enfants de La Chaise.* Thèse de doctorat, Université de Perpignan.
- TILLIER A.-M., 1983. Le crâne d'enfant d'Engis 2: un exemple de distribution des caractères juvéniles, primitifs et néandertaliens. *Bulletins de la Société royale belge d'Anthropologie et de Préhistoire*, **94**: 51-75.
- TILLIER A.-M., 1989. The evolution of Modern Humans: Evidence from Young Mousterian Individuals. In: P. MELLARS & C. B. STRINGER (ed.), *The Human Revolution. Behavioural and Biological Perspectives on the Origins of modern Humans*. Edinburgh, Edinburgh University Press: 286-297.
- TRINKAUS E., 1983. *The Shanidar Neandertals*. New York, Academic Press: 502 p.
- TURNER II C. G., NICHOL C. R. & SCOTT G. R., 1991. Scoring procedures for key morphological traits of the permanent dentition: the Arizona State University Dental Anthropology System. In: M. A. KELLEY & C. S. LARSEN (ed.), *Advances in Dental Anthropology*. New York, Wiley-Liss Inc.: 13-31.
- WALKER M. J., GIBERT J., LÓPEZ M. V., LOMBARDI A. V., PÉREZ-PÉREZ A., ZAPATA J., ORTEGA J., HIGHAM T., PIKE A., SCHWENNINGER J.-L., ZILHÃO J. & TRINKAUS E., 2008. Late Neandertals in Southeastern Iberia: Sima de las Palomas del Cabezo Gordo, Murcia, Spain. *Proceedings of the National Academy of Sciences USA*, **105**: 20631-20636.

#### AUTHORS AFFILIATION

Isabelle CREVECOEUR  
Bruno MAUREILLE  
CNRS  
PACEA, UMR 5199  
Allée Geoffroy St Hilaire  
CS 50023  
33615 Pessac cedex  
France

[i.crevecœur@pacea.u-bordeaux1.fr](mailto:i.crevecœur@pacea.u-bordeaux1.fr)  
[b.maureille@pacea.u-bordeaux1.fr](mailto:b.maureille@pacea.u-bordeaux1.fr)

Isabelle CREVECOEUR  
Hélène ROUGIER  
Earth and History of Life  
Royal Belgian Institute of Natural Sciences  
29, Vautier Street  
1000 Brussels  
Belgium

Hélène ROUGIER  
Department of Anthropology  
California State University Northridge  
18111 Nordhoff Street  
Northridge, CA 91330-8244  
USA  
[helene.rougier@csun.edu](mailto:helene.rougier@csun.edu)